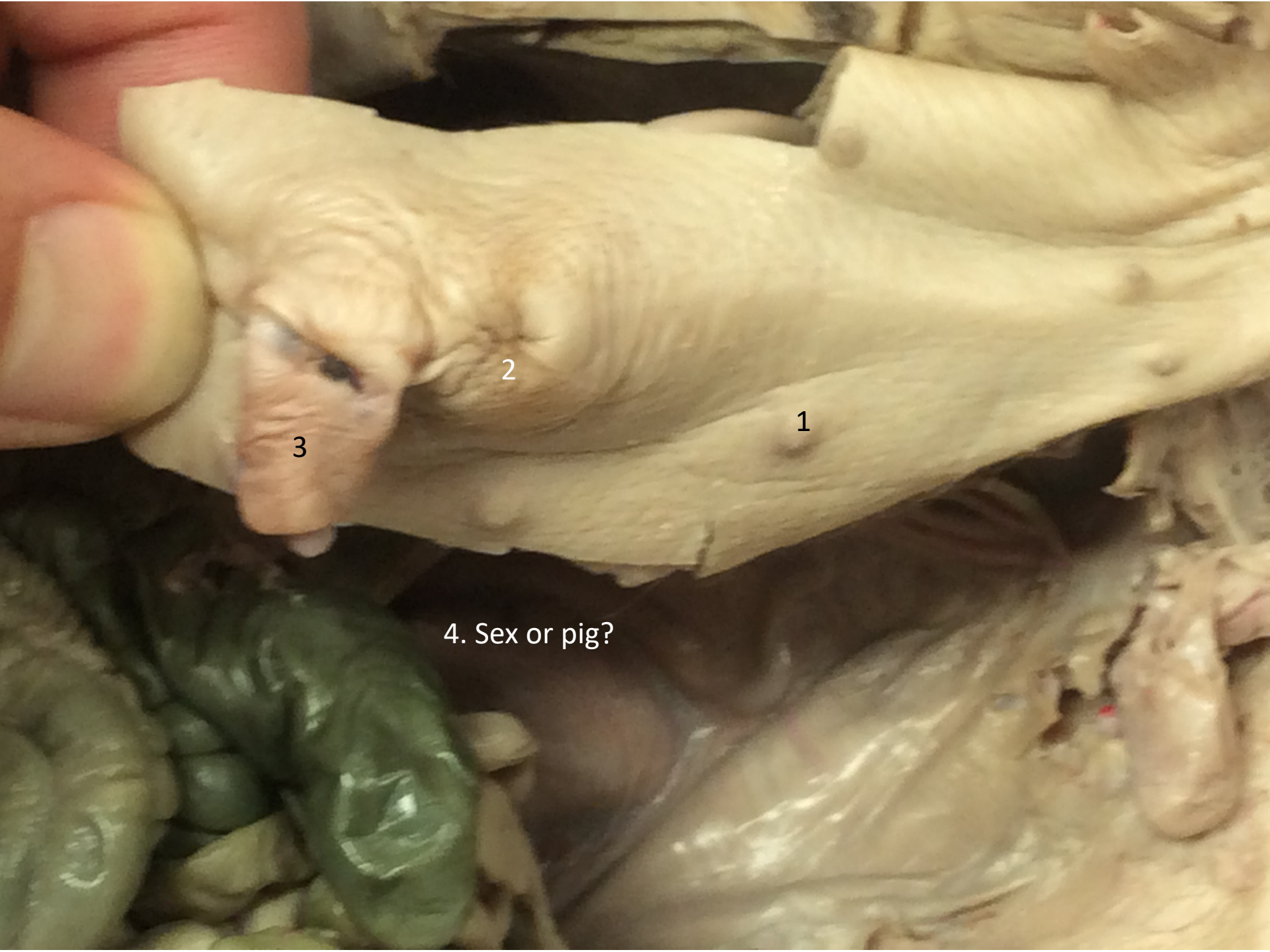




2

1

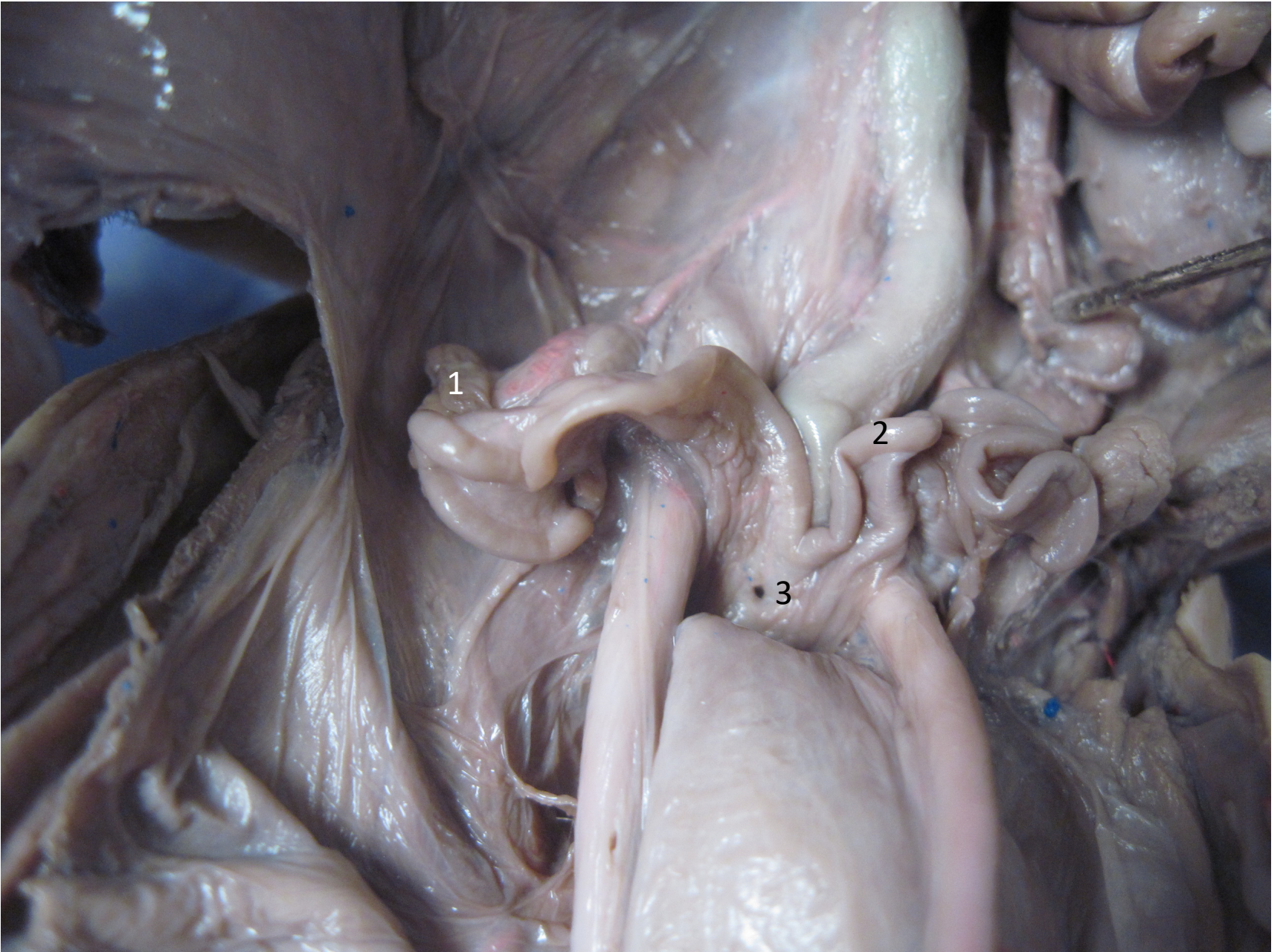
3

4. Sex or pig?

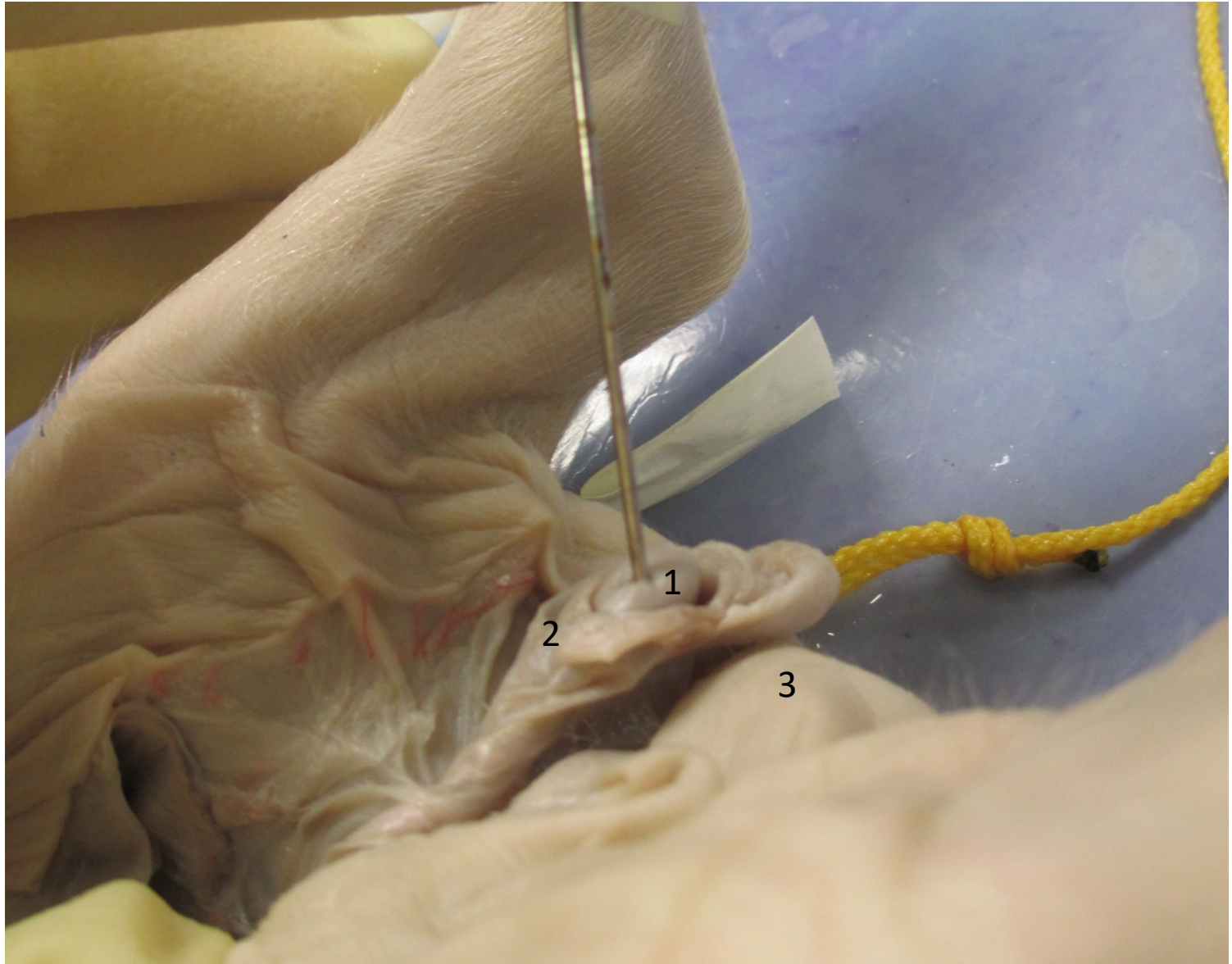
1. Mammillae papillae
2. Urogenital opening
3. Umbilical cord
4. Male



1. Umbilical vein
2. Peritoneum
3. Liver

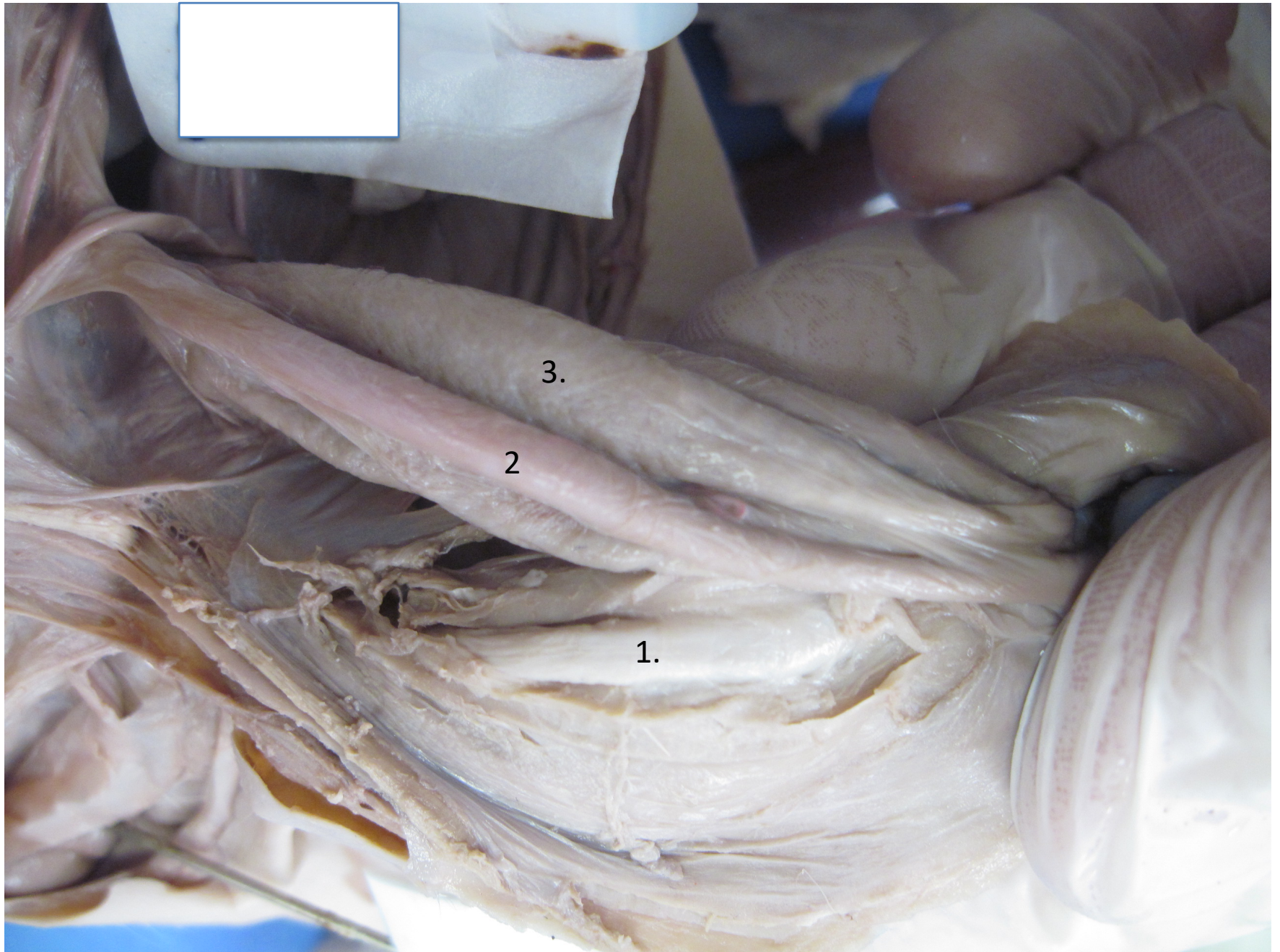


1. Ovary
2. Fallopian (uterine) tube
3. Uterus



1. Testis
2. Epididymus
3. Scrotum



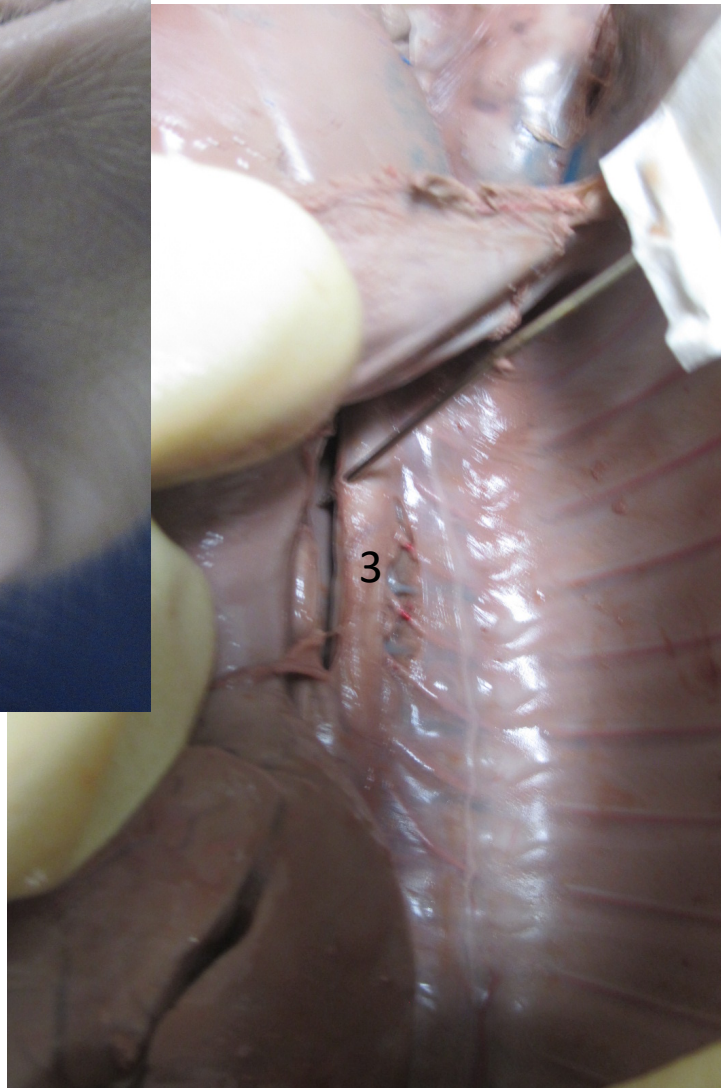
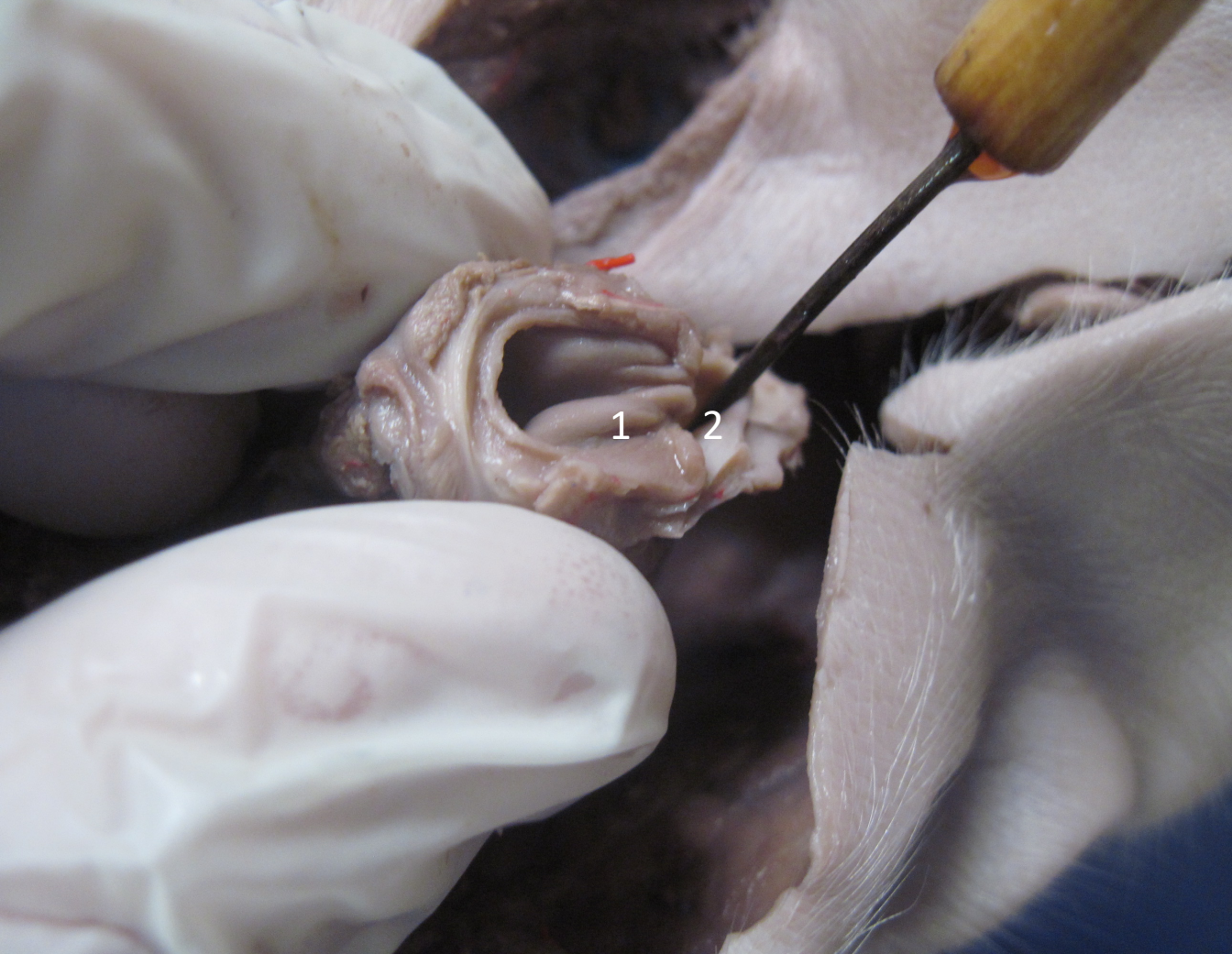

3.

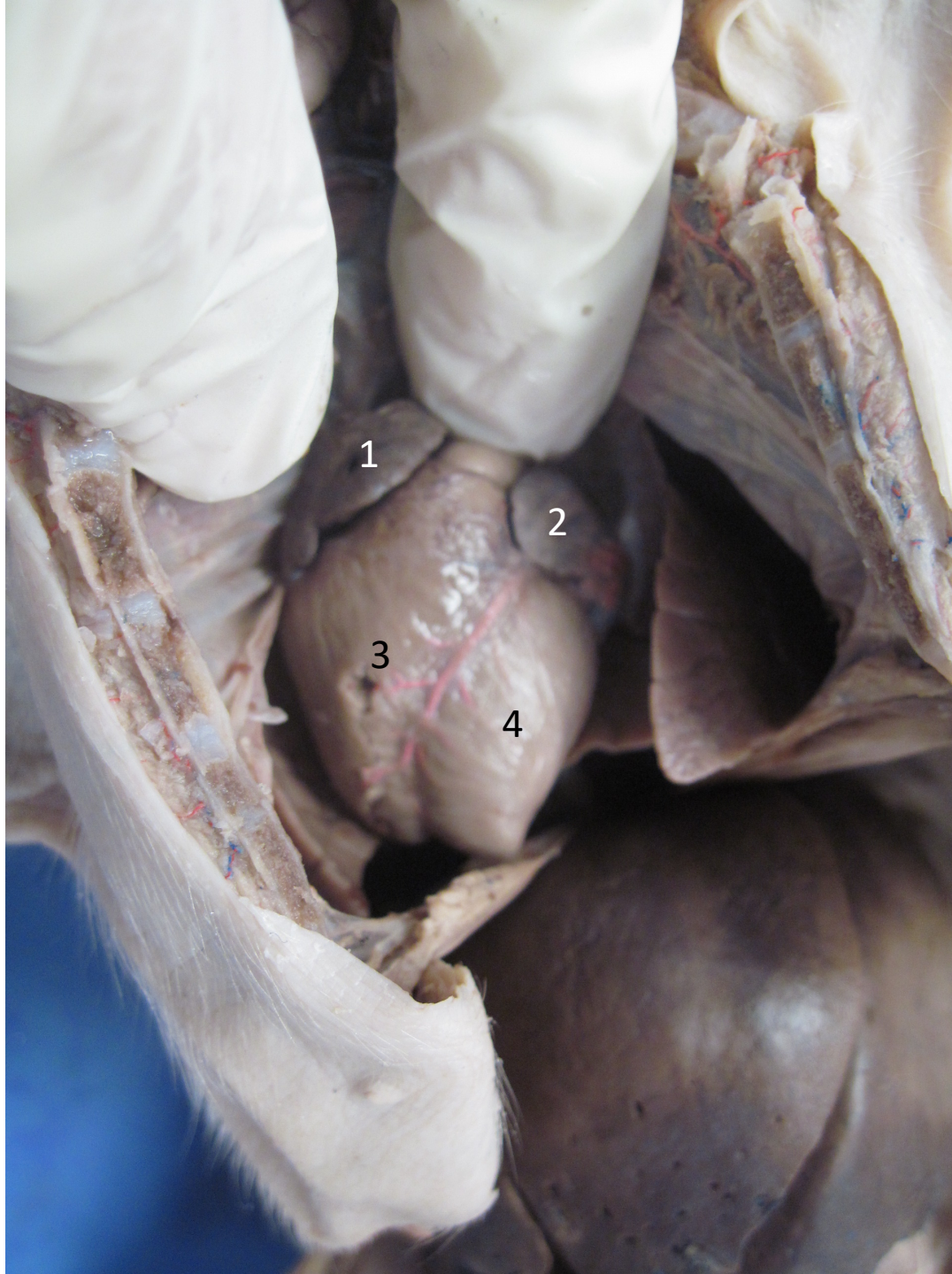
2.

1.

1. Penis
2. Umbilical artery
3. Urinary bladder



1. Vocal folds
2. Esophagus
3. Dorsal aorta



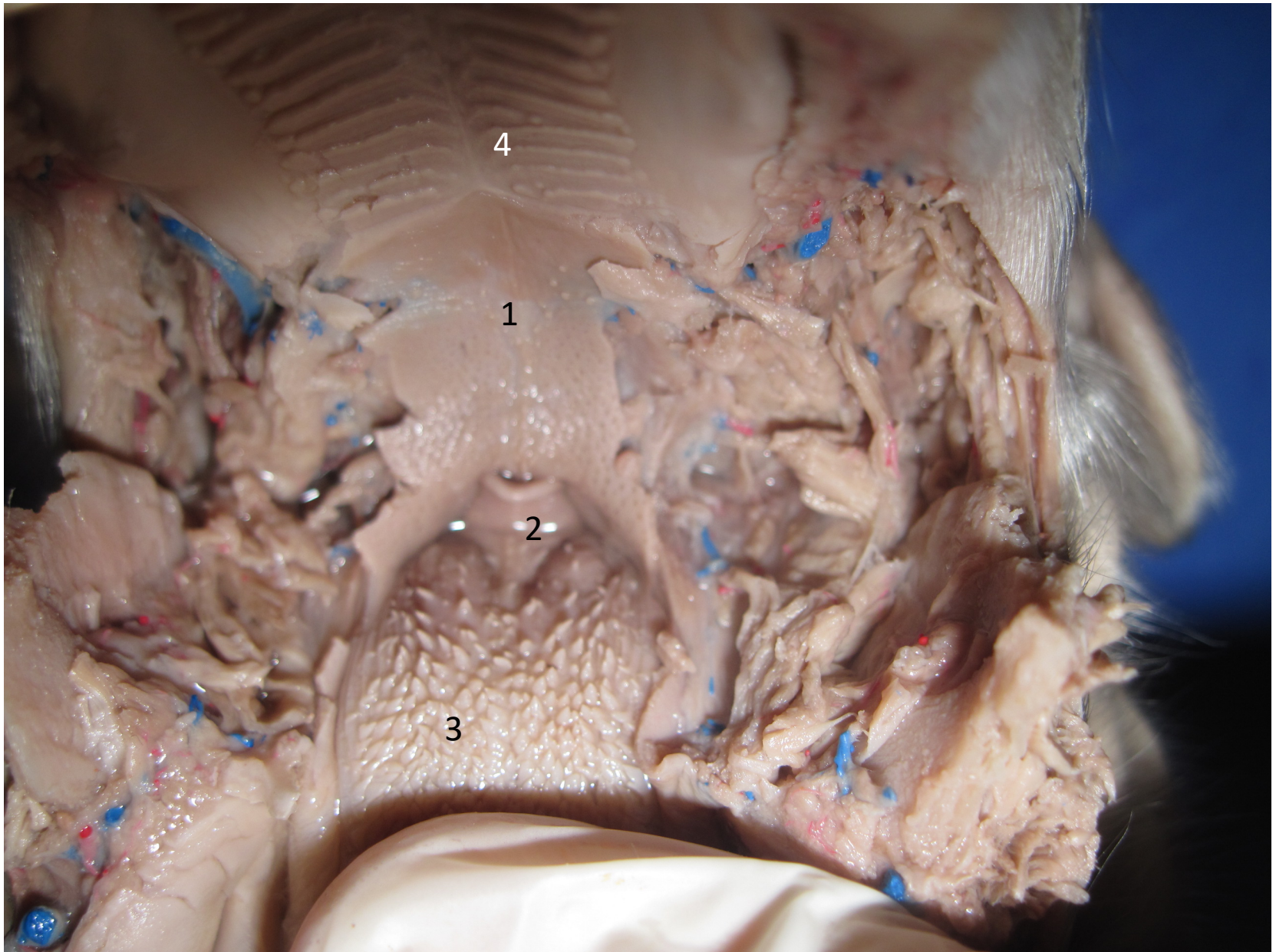
1

2

3

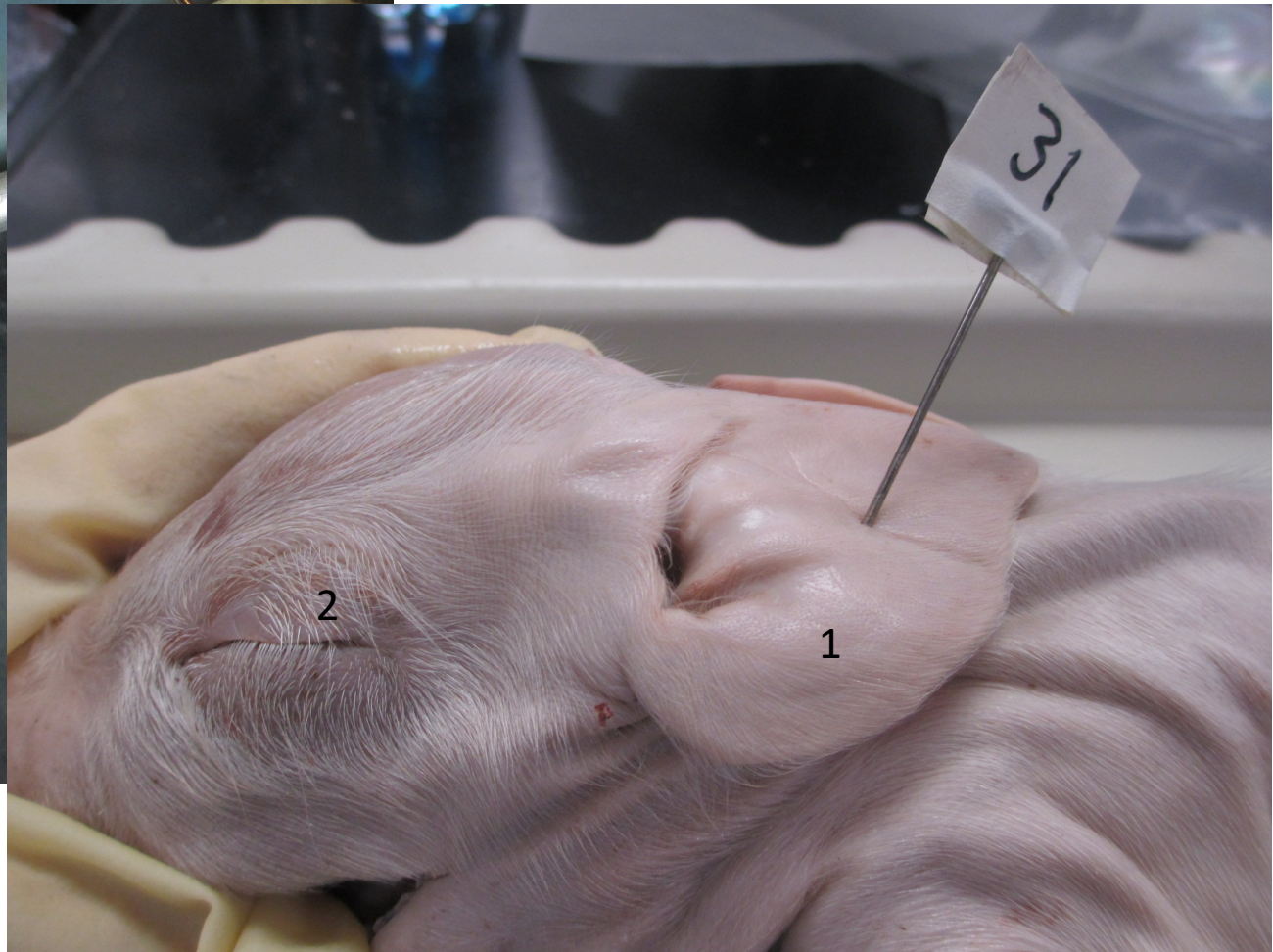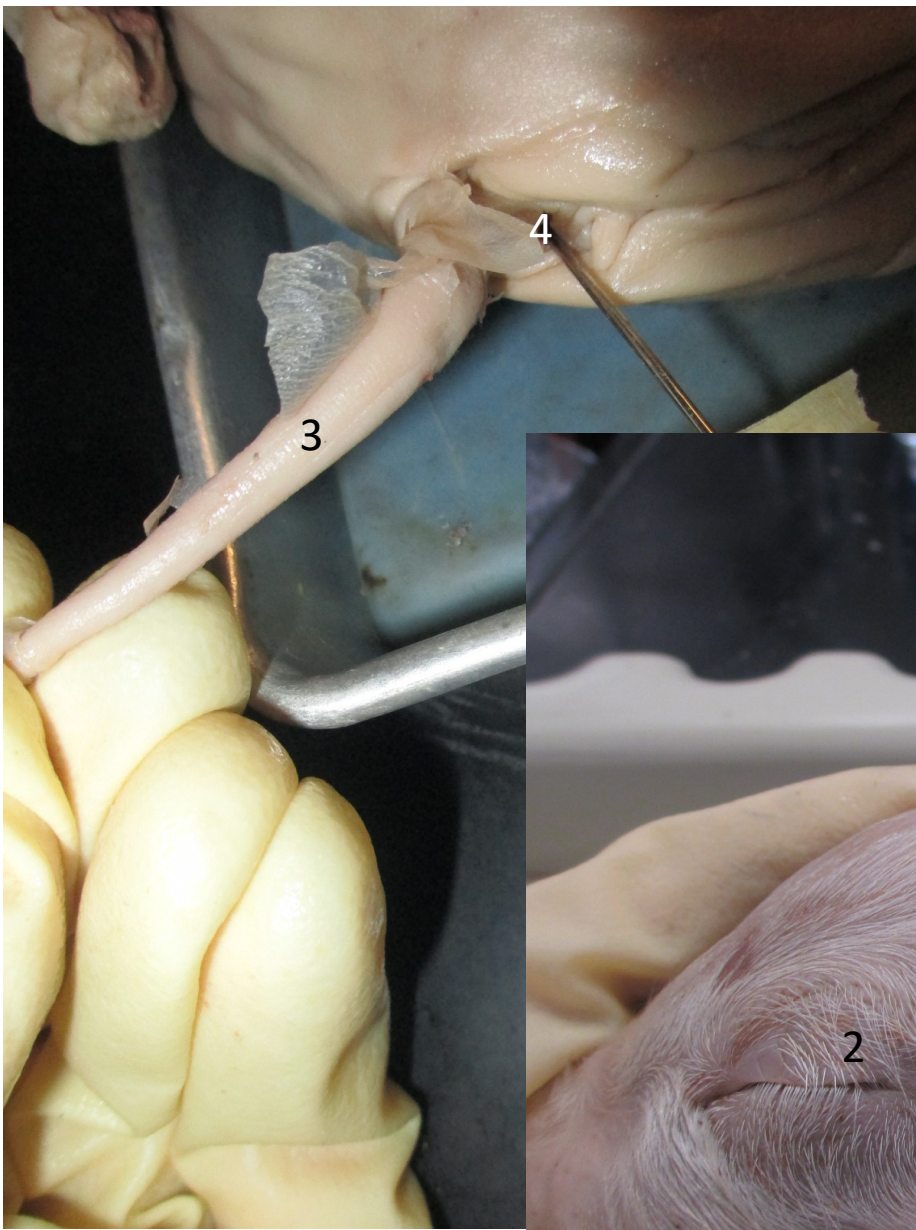
4

1. Right atrium
2. Left atrium
3. Right ventricle
4. Left ventricle



1. Soft palate
2. Epiglottis
3. Papillae on tongue
4. Hard palate





1. External pinnae
2. Eyelid
3. Tail
4. Anus